

*The clinical experience and efficacy of
radiofrequency device for wrinkle treatment*


**Yeon A No, Beom Joon Kim, Myeung
Nam Kim & Chang Kwun Hong**

Lasers in Medical Science

ISSN 0268-8921

Lasers Med Sci

DOI 10.1007/s10103-017-2206-x



 Springer

Your article is protected by copyright and all rights are held exclusively by Springer-Verlag London. This e-offprint is for personal use only and shall not be self-archived in electronic repositories. If you wish to self-archive your article, please use the accepted manuscript version for posting on your own website. You may further deposit the accepted manuscript version in any repository, provided it is only made publicly available 12 months after official publication or later and provided acknowledgement is given to the original source of publication and a link is inserted to the published article on Springer's website. The link must be accompanied by the following text: "The final publication is available at link.springer.com".

The clinical experience and efficacy of radiofrequency device for wrinkle treatment

Yeon A No¹ · Beom Joon Kim¹ · Myeung Nam Kim¹ · Chang Kwun Hong¹

Received: 12 January 2016 / Accepted: 6 April 2017
© Springer-Verlag London 2017

Dear Editor:

Radiofrequency devices (RF) have been used to destroy cancer cell using heat generation by the high frequency current. But they also become known for skin tightening, dermal remodeling, and skin regeneration effect after using on the skin [1].

A 60-year-old man and a 64-year-old woman presented with fine wrinkles on their periorbital and perioral areas (Figs. 1a and 2a). We used the newly developed RF device which name is AGNES[®] (Gowoonsesang Cosmetics.co., Ltd., Seoul, Korea) which can disperse the energy to depth of wrinkles without leaving scars due to insulation of their epidermal point of contact.

The anesthetic creams were applied for 30 min on face and we marked along wrinkles on periorbital and perioral areas. Then patients were laid back on the chair, needles were inserted with 3–5-mm intervals on the wrinkles. A high frequency current was applied at 120 msec, an intensity of power level 2 with 1 MHz RF apparatus. Procedure time was about 5–10 min and an ice cooler was needed on the treated lesions. Assessments of clinical improvement were performed

at base and after 4 weeks of treatments by one dermatologist. Clinical improvement was also based on the subjective satisfaction of the patients using a visual analogue scale (VAS, 0–7, 0—not at all satisfied, 7—very satisfied). After 4 weeks, both patients demonstrated a marked reduction in the size and depth of their lesions (Figs. 1b and 2b) and had high satisfaction (VAS score, 5). Other than transient mild erythema and pain, they had no adverse effects such as scarring and hyperpigmentation related to epidermal damage.

Of the various devices that have been used to correct wrinkles and laxity, RF is thought to be highly effective and is frequently used in worldwide [2, 3]. Yusuke et al. reported that after monopolar RF treatment for skin rejuvenation, type I and III of collagen significantly increased after irradiation in the dermis ($p < .05$), and their changes were noticed uniformly in all layers [4].

Commonly used RF devices in cosmetic dermatology are microneedling fractional radiofrequency devices (MFRD). In contrast to MFRD, needle of AGNES has shorter insulated part (<0.5 mm) which make possible to transfer RF energy to more superficial tissue. For example, MFRD is impossible to be used on eyelid skin because of the skin depth is around 1 mm. Also, the shoulders of T-shape AGNES needle can function as a stopper which is essential to transfer energy with even depth regardless of different session or physician. Also, single-needle system make possible to deliver more electrical fluence to tissue than multi-needle system of MFRD. This selective dermal stimulation make neocollagenesis without epidermal damages then further

✉ Beom Joon Kim
beomjoon@unitel.co.kr

¹ Department of Dermatology, Chung-Ang University Hospital 224-1 Heukseok-dong, Dongjak-ku, Seoul 156-755, South Korea

Fig. 1 Improvement of periorbital wrinkles 4 weeks after the final treatment with AGNES[®]. **a** Before treatment. **b** After treatment

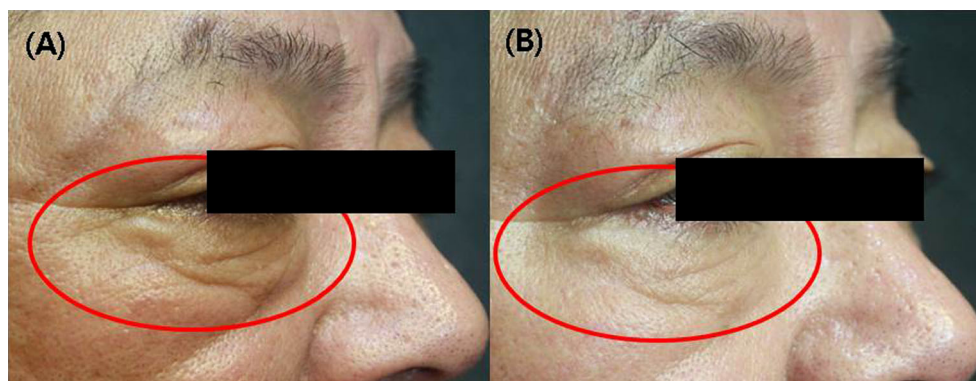
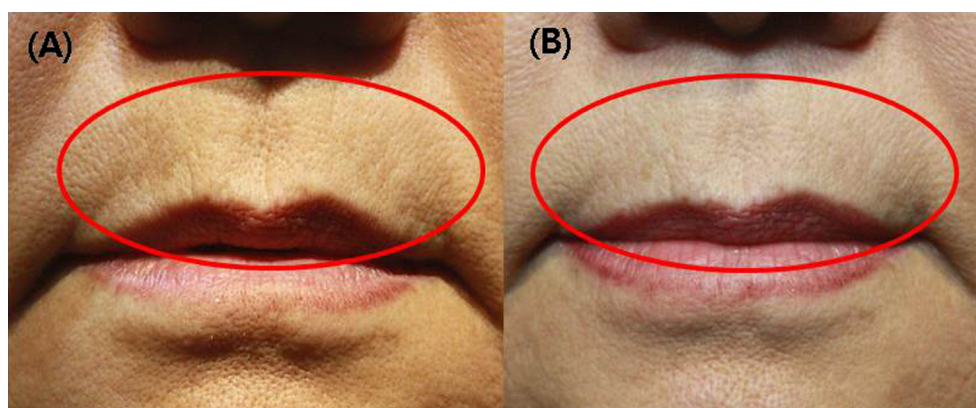


Fig. 2 Improvement of perioral wrinkles 4 weeks after the final treatment with AGNES[®]. **a** Before treatment. **b** After treatment



tightens the dermal tissue and help flatten and regenerate the wrinkles [1]. However, due to the necessity of injecting each individual lesion at 3–5-mm intervals, each session took a long time in comparison to botulinum toxin. And during procedure, pain and post-treatment erythema were observed but it was not last over 3 days.

In conclusion, a new treatment performed with an RF needle device may represent a safe and effective method for rejuvenation, especially in highly mobile areas, such as periorbital and perioral area. However, further studies with longer follow-up periods and larger sample sizes as well as more than one treatment sessions (probably at least three or four sessions) are needed.

Compliance with ethical standards The study was conducted in accordance with the principles of the Helsinki Declaration. All patients provided written informed consent prior to their inclusion in the study.

Conflict of interest The authors declare that they have no conflict of interest.

Funding sources This research was supported by a grant of the Korea Health Technology R&D Project through the Korea Health Industry

Development Institute (KHIDI), funded by the Ministry of Health & Welfare, Republic of Korea (grant number: HI17C1234).

Ethical approval This article does not contain any studies with human participants or animals performed.

Informed consent Informed consent was obtained from all individual participants included in the study.

References

1. El-Domyati M, El-Ammawi TS, Medhat W, Moawad O, Brennan D, Mahoney MG et al (2011) Radiofrequency facial rejuvenation: evidence-based effect. *J Am Acad Dermatol* 64: 524–535
2. England LJ, Tan MH, Shumaker PR, Egbert BM, Pittelko K, Orentreich D et al (2005) Effects of monopolar radiofrequency treatment over soft-tissue fillers in an animal model. *Lasers Surg Med* 37: 356–365
3. Kobayashi T, Tamada S (2007) Selective electrothermolysis of the sebaceous glands: treatment of facial seborrhea. *Dermatol Surg* 33: 169–177
4. Yokoyama Y, Akita H et al (2014) Histologic study of collagen and stem cells after radiofrequency treatment for aging skin. *Dermatol Surg* 40(4):390–397